

Immediate Reconstruction of the Thumb Using the Amputated Skeleton with a Tubed Pedicle Flap

MOHAMAD KHALED YOUSSEF, M.D.

The Department of Plastic and Reconstructive Surgery, Faculty of Medicine, Ain Shams University.

ABSTRACT

Thumb reconstruction is a real challenge to reconstructive surgeons. When amputation leaves a stump that is too short to allow grasp and pinch, reconstructive procedures are needed to regain thumb length. Pollicization, extraction lengthening, osteoplastic reconstruction, wrap-around technique and free toe-to-thumb transfer, are techniques to restore thumb length. In this article, the osteoplastic technique was modified to utilize the bones from the amputated thumb. Nine male patients-aged between nineteen and fifty-seven years-with amputated thumbs were included in this study. All of them had fresh amputations due to occupational hazards. Replantation could not be performed for reasons such as severe avulsion or crushing, severe lacerations, or improper preservation of the amputated thumb. The level of amputation was between the proximal part of the proximal phalanx and the distal part of the first metacarpal bone. The amputated elements were filleted and fixed to the stump and covered by a tubed abdominal groin flap. All reconstructed thumbs were cosmetically acceptable. Functionally, the reconstructed thumbs were stable enough to provide a post for grip, pinch and opposition by the remaining fingers. This technique provides a method to reconstruct the amputated thumb immediately if replantation is not possible. The main advantage is that it utilizes skeletal elements from the amputated parts and does not call for bone graft donor sites.

INTRODUCTION

The thumb is considered a crucial element in hand function. Loss of thumb function constitutes a great deficit. The ability to reconstruct a truly useful thumb is a real challenge. The reconstructed thumb must have sufficient length to oppose the remaining fingers, stability to allow strong pinch, adequate sensation and freedom from pain [1]. In many instances an amputated thumb can be replanted using microsurgical techniques.

Replantation allows for excellent return of sensibility, restoration of near normal length and

generally leads to faster return of function and better cosmetic appearance. In some amputations and mutilating injuries replantation of the thumb is not possible and an alternative technique should be adopted. The choice of technique largely depends upon the level of loss. Injury at the level of the distal one-third of the thumb results in loss of the volar tactile pad which needs soft tissue coverage only. Amputation through or proximal to the middle third of the thumb leaves inadequate length for useful grasp and requires procedures aimed at restoration of length.

Many techniques have been used to increase thumb length; phalangization of the first metacarpal bone (first web space deepening by Z-plasty or four flap technique with or without muscle release) [2,3], transposition of an injured index to the thumb (pollicization) [4], gradual extraction lengthening of first metacarpal bone [5], osteoplastic reconstruction by autologous bone graft and tubed abdominal flap [6], microvascular transfer of soft tissue from big toe (wrap-around technique) [7] and free great toe to thumb transfer [8]. In this series, the osteoplastic technique was modified to utilize bone elements from the amputated thumb instead of iliac bone grafts.

PATIENTS, TECHNIQUE AND RESULTS

Nine male patients with amputated thumbs were included in this study. Age of the patients ranged between nineteen and fifty-seven years. The right hand was affected in five cases and the left hand was affected in four cases. All of the patients had fresh amputations which were not indicated for reimplantation for reasons such

as severe avulsion or crushing injury in six cases, two severely lacerated amputations and one case with badly preserved amputated part with long warm ischemia. The level of the amputation was in the proximal part of the proximal phalanx in seven cases and in the distal part of the first metacarpal bone in two cases. Amputation of the thumb was an isolated injury in eight cases and combined with the index finger in one case. The amputated parts were filleted in a sub-periosteal plane. The articular surfaces of the interphalangeal joint and/or metacarpophalangeal joint were arthrodiesed in the position of best function that allows the reconstructed thumb to be opposed to the remaining fingers. Fixation of bone was by K-wire and/or interosseous wire loops. Ipsilateral groin flap was used in six cases and ipsilateral transverse abdominal flap was used in three cases. The skin flap was completely tubed around the bone graft. All flaps survived. Division of the flap was done after four weeks to allow for vascular connection to establish between the graft and soft tissue. Subsequent de-bulking of the flap was needed in seven cases two to three months postoperatively. An osteomyelitic terminal phalanx was removed in one case and the proximal phalanx survived the reconstruction. Extensive physiotherapy programme was scheduled postoperatively in every case.

All reconstructed thumbs were functionally and cosmetically acceptable. All nine patients were satisfied with the result. The major drawback of this technique was absence of sensitivity. Temperature, pain and touch sensation were absent immediately after reconstruction. With time the flap gained deep and vague sensibility that was not protective. Patient follow-up ranged between three to twelve months.

DISCUSSION

Reimplantation of the amputated thumb provides the best possible functional and cosmetic result. In some situations microvascular reimplantation is not possible due to type of injury or due to lacking of facility. In such cases thumb reconstruction can be achieved using different techniques such as phalangization, pollicization, bone lengthening, wrap-around technique or toe-to-thumb transfer.

Phalangization deepens the first web space

and adds one to two centimeters of apparent length but if the thumb is too short for pinching and opposition it will be of no value. Pollicization is a useful technique if the index finger is injured otherwise it will sacrifice a normal finger. Bone lengthening is a lengthy procedure and may be jeopardized by soft tissue scars or bone fractures.

Also it may be limited by increased stretch of the neurovascular bundles. Wrap-around technique and toe to thumb transfer by microsurgical technique provides good replacement but their donor site morbidity is to be considered. Osteoplastic reconstruction by abdominal flap wrapped around the filleted amputated thumb bones provides acceptable results with the morbidity of the donor site of the abdominal flap. In this series patients were reconstructed with acceptable results as regards appearance. The reconstructed thumbs were of adequate length and stability that they provided a stable post against which other fingers could be opposed. The most defective aspect of thumbs reconstructed by this technique was sensation which was vague and not protective at the base and almost absent at the tip of the reconstructed thumb.

Conclusion:

This article presents a modification of an old technique. This technique is able to present reproducible results. Compared to more sophisticated methods of thumb reconstruction like wrap-around and toe-to-thumb transfer, it produces less than ideal result regarding sensibility and mobility. But it produces excellent results if the aim of reconstruction is to establish a post against which other fingers are to be opposed. Also, it is considered a salvage procedure to the bony elements of the amputated thumb whenever microsurgical reimplantation is not available or the condition of the amputated thumb is not suitable for reimplantation. Surgically it is not demanding and it avoids donor site morbidity of bone grafts.

REFERENCES

- 1- Nunley J.A.: Basic principles of reconstruction of the thumb. In: Georgiade N.G., Georgiade G.S., Riefkohl R. and Barwick W.J. (Eds): *Essentials of Plastic, Maxillofacial and Reconstructive Surgery*. Williams and Wilkins, 1987.
- 2- Howard L.D.: Contracture of the thumb web. *J. Bone Joint Surg.*, 32A: 267, 1950.

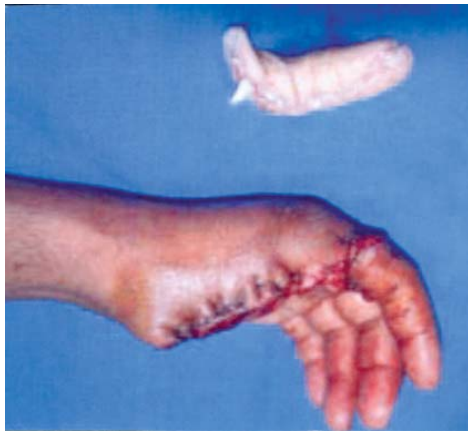

Fig. (1-A): Pre-operative view of case No. 1. Amputated left thumb at MPJ level by electric saw with longitudinal lacerations along the volar surface.

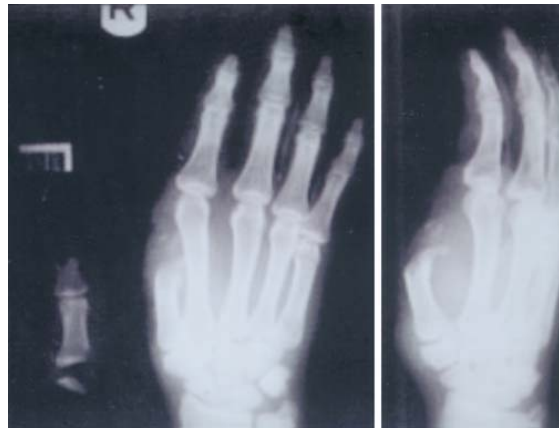

Fig. (1-B): Pre-operative X-ray.

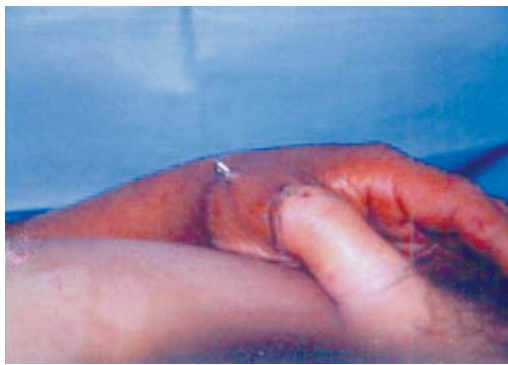

Fig. (1-C): Tubed ipsilateral groin flap.

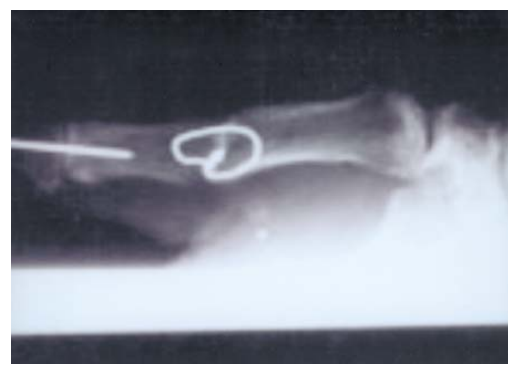

Fig. (1-D): Arthrodesis of MPJ by wire loop and the IPJ by K-wire.

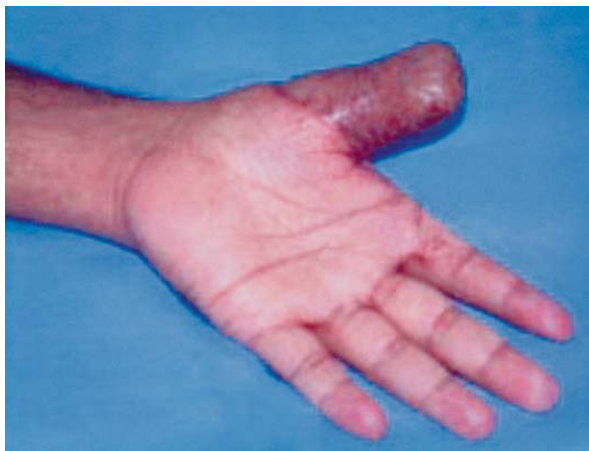

Fig. (1-E): Post-operative view of the flap.

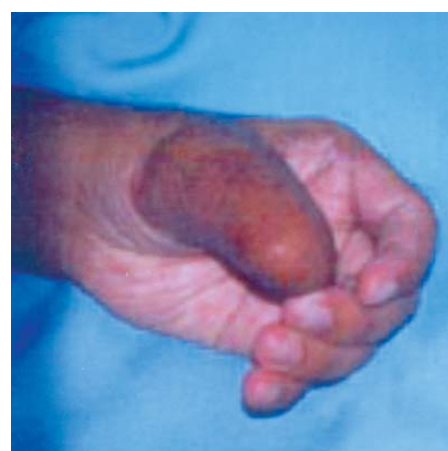

Fig. (1-F): Opposition of the fingers to the thumb.

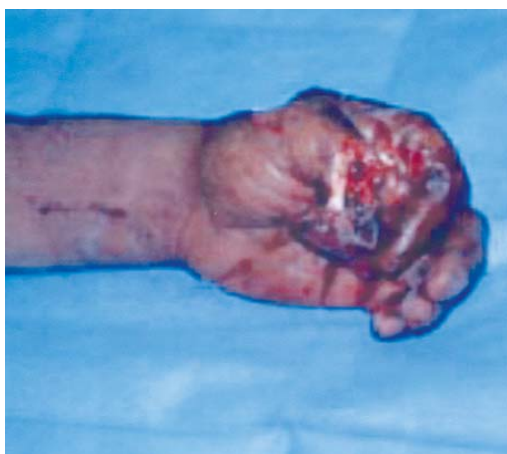

Fig. (2-A): Pre-operative view of case No. 2. Severe crushing of the proximal phalanges of the left thumb and index.

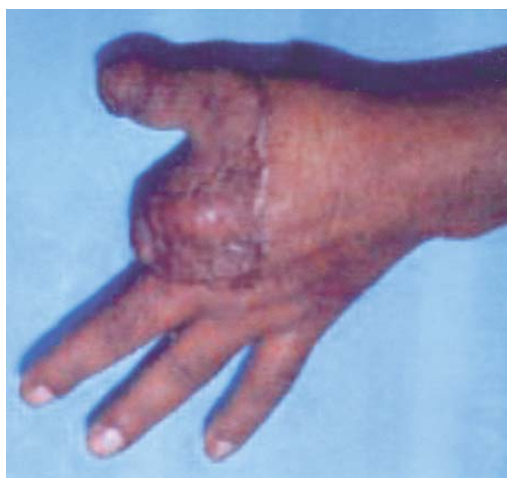

Fig. (2-B): Post-operative view.

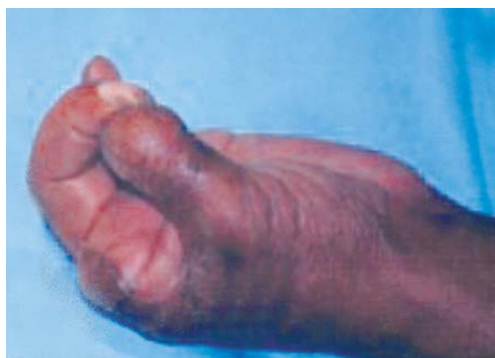

Fig. (2-C): Opposition of the middle finger to the thumb.

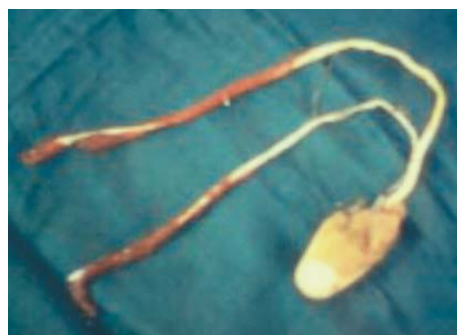


Fig. (3-A): Pre-operative view of case No. 3. Severe avulsion of half of the right thumb.

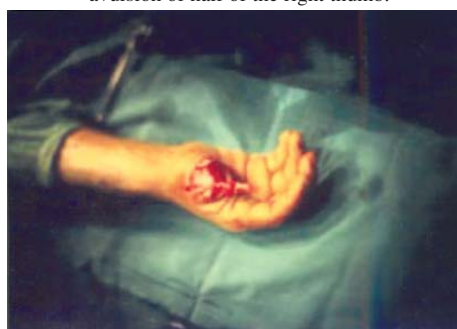

Fig. (3-B): Fixation of the filleted distal phalanx to the amputation stump.

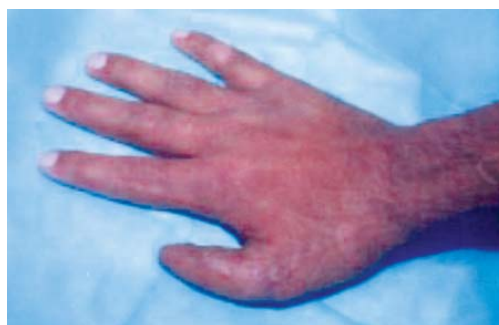

Fig. (3-C): Late post-operative view.

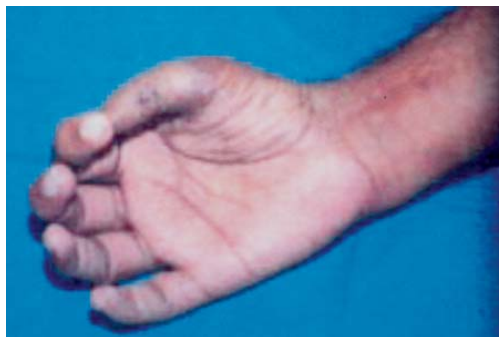

Fig. (3-D): Opposition of the fingers.

- 3- Woolf R.M. and Broadbent T.R.: The four flap Z-plasty. *Plast. Reconstr. Surg.*, 49: 48, 1972.
- 4- Reid D.A.: Reconstruction of the mutilated hand. In: Rob N.C., Smith R., Pulvertaft R.G. (Ed): *Operative Surgery: The Hand*. 3rd edition, London, Butterworth, 1977.
- 5- Matev I.V.: Thumb reconstruction through metacarpal bone lengthening. *J. Hand Surg.*, 5: 482, 1980.
- 6- Barsky A.J.: Restoration of the thumb by transplantation, plastic repair and prosthesis. *Surgery*, 23: 227, 1984.
- 7- Morrison W.A., O'Rien B.M. and MacLeod A.M.: Thumb reconstruction with a free neurovascular wrap-around flap from big toe. *J. Hand Surg.*, 5: 575, 1980.
- 8- O'Brien B.M., Brennen M.B. and MacLeod A.M.: Microvascular free toe transfer. *Clin. Plast. Surg.*, 5: 223, 1978.